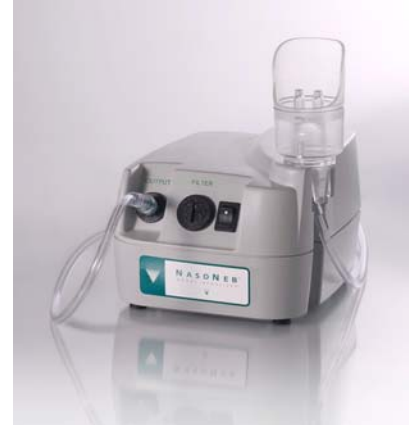

Case Study: Resolution of Nasal Polyps in a 73 year old male with recurrent nasal polyps after 4 week of intranasal steroid therapy delivered by NasoNeb™ Nasal Nebulizer

Steven F. Isenberg, M.D.¹

Summary: A **73 year old male** with a two-three decade history of recurrent nasal polyps associated with chronic sinusitis presented with complaints of nasal blockage, anosmia and disruption of sleep. Prior treatments include 2 surgeries (1986 and 2008) for nasal polyposis and chronic sinusitis. Endoscopic exam revealed evidence of recurrent inflammatory polyps. Following a 4 week therapy of Budesonide (0.6 mg bid) formulated for inhalation therapy by a specialty pharmacy and delivered by NasoNeb™ Nasal Nebulizer (MedInvent, LLC White Bear Lake, MN), endoscopic exam revealed polyps had resolved, inflammation was greatly reduced and the need for a third surgery was eliminated.



History: A 73 year old male with recurrent nasal polyps was seen on a return visit in February, 2010, with complaints of nasal blockage, anosmia and disruption of sleep. He has a history of nasal polyps dating prior to his initial visit to his otolaryngologist in 1986. Significant history includes at least 2 CT scans of his sinuses, numerous cortisone nasal sprays, antihistamines, decongestants, intranasal cortisone injections and two surgeries to remove nasal polyps and perform endoscopic sinus surgery. He stated his first surgeon “got near nerves and needed to stop,” so he “had to leave some of the polyps.” His CT scan prior to his second surgery demonstrated “extensive sinusitis with abnormal soft tissue consistent with nasal polyps.” At his second surgery in June, 2008, numerous polyps were removed from the maxillary sinus that were obstructing the iatrogenic opening and throughout the paranasal area including the sphenothmoidal area.

between the middle turbinate and the nasoseptal cartilage on the left side.

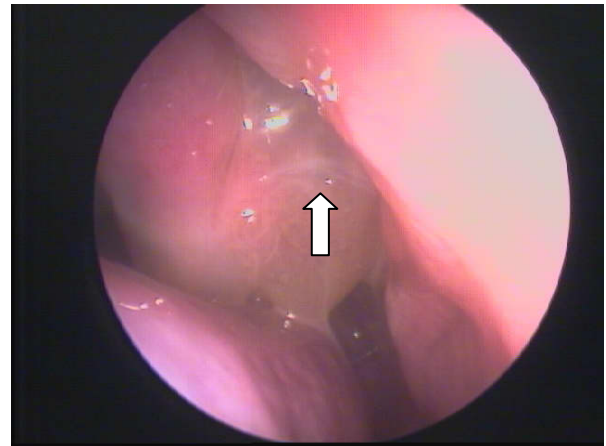


Photo 1. Nasal Polyps superior to the right middle turbinate

On a return visit in February, 2010, an endoscopic exam revealed inflammatory nasal polyps lying superior to the right middle turbinate (photo 1). Photo 2 demonstrates a polyp

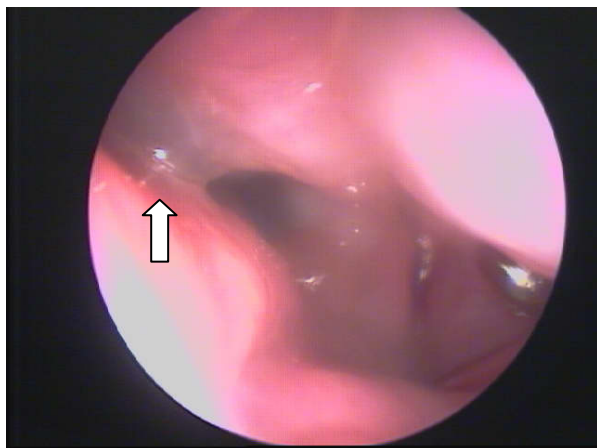


Photo 2. Polyp between the middle turbinate and the nasoseptal cartilage on the left side

Prior to performing a third functional endoscopic sinus surgery, the patient was prescribed a 4 week course of intranasal Budesonide (0.6 mg, bid) delivered by the NasoNeb Nasal Nebulizer. The patient was asked to return after 4 weeks of treatment for a follow up visit.

Results: At 4 weeks, after treatment with Budesonide (0.6 mg, bid) delivered by NasoNeb Nasal Nebulizer; nasal endoscopy was performed and revealed complete elimination of nasal polyps and a reduction of inflammation. Nasal blockage, anosmia, and sleep disruptions have resolved.

Photos 3 and 4 demonstrate an anterior and posterior view of the left nasal vestibule. Photos 5 and 6 demonstrate a posterior and anterior view of the right nasal vestibule. All polyps and polypoid changes in the nasal vestibule have resolved.

The patient was placed on a maintenance therapy of NasoNeb Nasal Nebulizer treatments with Budesonide (0.6 mg, every third day) with isotonic saline irrigation recommended on the intervening days.

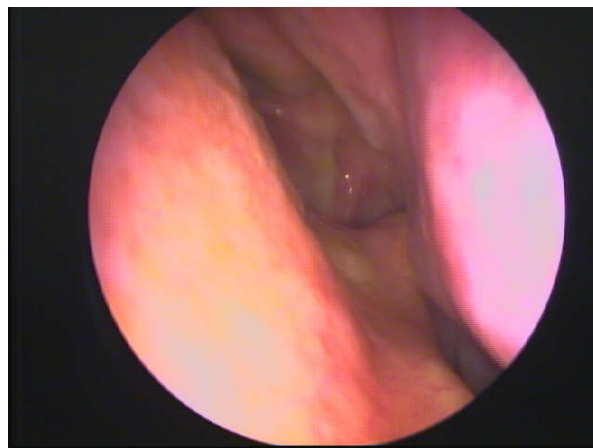


Photo 3. Anterior view of the left nasal vestibule

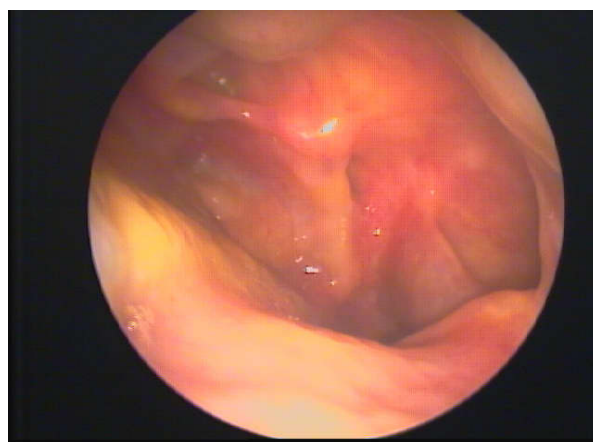


Photo 4. Posterior view of the left nasal vestibule

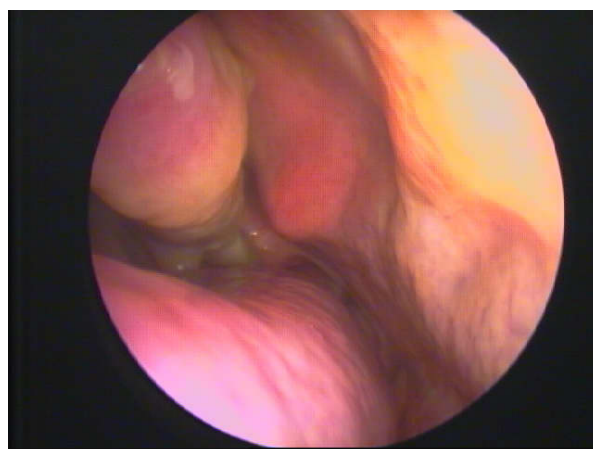


Photo 5. Posterior view of the right nasal vestibule

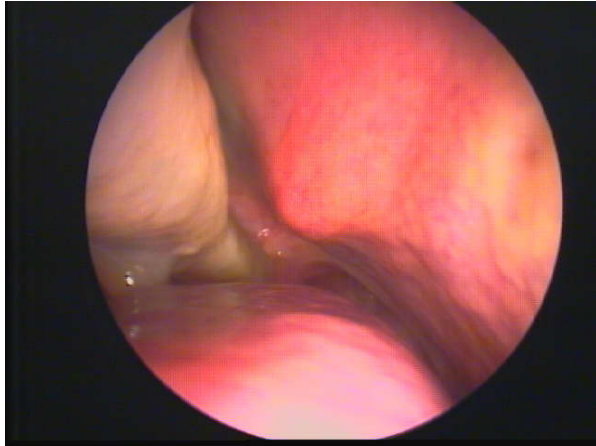


Photo 6. Anterior view of the right nasal vestibule

Discussion: The NasoNeb Nasal Nebulizer creates a large particle aerosol. The force imparted by the air column provides a level of momentum to these particles that appears to enable the irrigating fluid to reach the whole nasal cavity.

As is the case with the patient presented here, surgery may relieve symptoms from nasal polyps but does not correct the underlying cause of recurrent nasal polyposis. Topical steroids have been shown to be effective in the treatment of nasal polyps, thus avoiding surgery. The NasoNeb Nasal Nebulizer was successful in delivering the drug where other steroidal nasal sprays failed.

Conclusion: The twice-a-day topical application of Budesonide via the Nasoneb Nasal Nebulizer resolved the need for additional surgery in this adult male patient who had undergone two previous nasal polypectomies and endoscopic sinus surgeries. The patient reports he can now smell, breathe and sleep without any difficulty. Previous efforts to control his nasal polyps and sinusitis with antihistamine and steroid nasal sprays, antibiotics and oral antihistamines and cytokine inhibitors were unsuccessful.

1. Steven Isenberg MD has been practicing Otolaryngology- Head and Neck surgery in Indianapolis, Indiana, for 30 years.

Disclaimer: Steven Isenberg is a principal in Med invent, LLC, manufacturer of the NasoNeb Powered Nasal Irrigator.

© 2010, MedInvent, LLC

NasoNeb and MedInvent are trademarks of MedInvent, LLC

N A S O N E B™
N A S A L N E B U L I Z E R

